

ABSTRACTS

ABSTRACT #

Analysis of the area sampled during prostate biopsies

C. Torterotot¹, P. Mozer^{1,2}, MA. Vitrani¹

¹ ISIR laboratory, University Pierre and Marie Curie, CNRS-UMR7222, Paris, France

² La Pitié-Salpêtrière hospital, urology dept, Paris, France

Introduction: Prostate cancer is the most common non-skin cancer in men and the second leading cause of cancer death among them. It is diagnosed by performing prostate biopsies using 2D Trans-Rectal Ultrasound probes equipped with a rigidly attached guide for spring needle guns. The procedure is challenging and the punctures locations are not well known (the gland moves and gets deformed). We managed to extract the surface of the prostate sampled and we think this data could be related to post-examination complications or to the efficiency of the cancer detection.

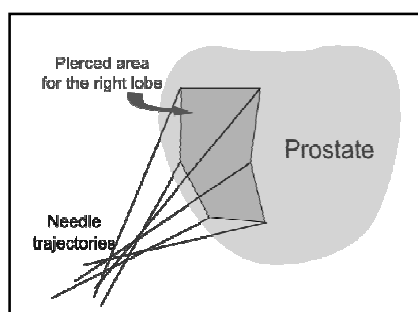


Figure 1: Pierced area in the prostatic capsule for the right lobe

Methods: In order to increase prostate biopsy accuracy a device called UroStationTM has been developed (Koelis [1]). It is based on a 3D TRUS linked to a computer with a network cable. Using image-based registration algorithm [2] the UroStationTM is able to give geometric information in a fixed reference space with respect to the prostate. The biopsy gun pushes the needle in the prostate on 22 millimeters and the needle orientation is given by the TRUS probe. So using the needle tip coordinates and the probe orientation, one can derive the coordinates of the needle entry point in the prostatic capsule. We developed an algorithm able to calculate the pierced area in each prostate lobe during the first twelve biopsies, which follow a “sextant scheme” [Figure 1].

Results: We used data recorded on 78 patients subject to navigation-assisted prostate biopsies. The examinations have been performed by three different urologists between January and November 2009. The pierced surface varies a lot between individuals and has a tendency to be correlated with the prostatic volume [Figure 2]. The averaged pierced area for one lobe is about 1 cm² only. It also appeared that the left lobe pierced surface is in average bigger than the right lobe one.

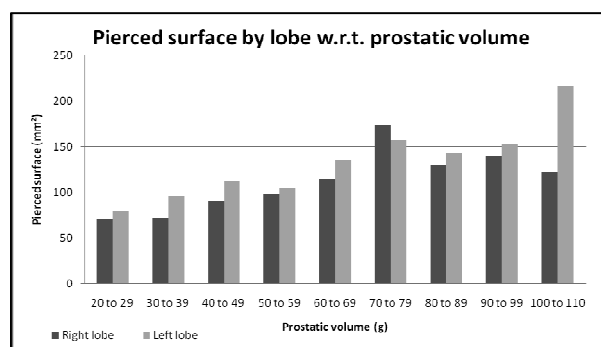


Figure 2: Value of the pierced area in each lobe, depending on prostatic volume

Conclusion: The study of the pierced area brings really new information. It appears that the pierced area is more important for the left lobe than for the right one. This could be due to a weaker precision during the biopsy of the left lobe, which results in an underestimation of the probe displacement by the surgeon. The results we get also indicate that patients undergo very different examinations one from the other, that probably don't have the same accuracy in cancer detection. A new study, crossing these results with medical data such as cancer detection is currently performed.

References:

[1] <http://www.koelis.com>

[2] M. Baumann, P. Mozer, V. Daanen, and J. Troccaz, Towards 3D Ultrasound Image Based Soft Tissue Tracking: A Transrectal Ultrasound Prostate Image Alignment System, MICCAI 2007